PAKISTAN JOURNAL OF Cardiovascular Intervention

OPEN ACCESS

CASE REPORT

A Therapeutic Paradox: Concomitant Cerebral Venous Sinus Thrombosis With Hemorrhagic Venous Infarction and Clinically Silent Acute Myocardial Infarction.

Kaleemullah Shaikh, Muhammad Asad Baqai & Muhammad Abdullah Sheikh
Department of Cardiology, Liaquat National Hospital and Medical College, Karachi, Pakistan.

Copyright © The Author(s). 2026 This is an open-access article distributed under the terms of the Creative Commons Attribution 4.0 International License, which permits unrestricted use, distribution, and reproduction in any medium, provided the original author and source are credited.

Citation:
Shaikh K, Baqai MA, Sheikh MA. A Therapeutic Paradox: Concomitant Cerebral Venous Sinus Thrombosis With Hemorrhagic Venous Infarction and Clinically Silent Acute Myocardial Infarction. PJCVI. 2026; 6(2): XX-XX

Corresponding Author Email:
kshaikh72@gmail.com

DOI: 10.58889/PJCVI.6.2.XX.XX

Funding:
This research received no specific grant from any funding agency in the public, commercial, or not-for-profit sectors.

Conflicts of Interests:
The authors declare no conflict of interest related to this publication.

Received 20/06/2026
Accepted 10/09/2026
First Published 23/11/2026

Abstract

Background: Concurrent cerebral venous thrombosis (CVT) with haemorrhagic venous infarction and acute myocardial infarction (AMI) creates competing thrombotic and bleeding risks. Haemorrhagic venous infarction due to CVT does not necessarily preclude anticoagulation.

Case Presentation: A 48-year-old man with diabetes and hypertension presented with progressive right-sided weakness, dysarthria, dizziness, confusion, and fluctuating consciousness. Glasgow Coma Scale was 13/15 and platelet count 98 × 10^9/L. Brain MRI showed a 4.6 × 4.3 × 4.6 cm left posterior parietal haemorrhagic venous infarction with oedema, mass effect, and 4-mm midline shift. MR venography demonstrated thrombosis of the superior sagittal, left transverse, and left sigmoid sinuses. Despite no chest pain, ECG showed inferior/inferoposterior ischaemic changes, troponin-I rose from 5.6 to 16.9 ng/mL, and echocardiography showed LVEF 45% with regional wall-motion abnormalities, supporting clinically silent AMI. Coronary angiography was deferred because of intracranial bleeding risk.

Management and Results: Enoxaparin 1 mg/kg every 12 hours was initiated with aspirin 100 mg/day. Dual-antiplatelet therapy was avoided because of intracranial haemorrhage, thrombocytopenia, and concurrent anticoagulation. After stabilization, treatment was transitioned to rivaroxaban 20 mg/day. No neurological deterioration, significant bleeding, recurrent myocardial ischaemia, or haematoma expansion occurred. The patient regained full consciousness and independent mobility. Follow-up MRI showed reduction of the haemorrhagic infarction without progressive bleeding, while myocardial perfusion SPECT demonstrated a fixed inferior-wall perfusion defect.

Conclusion: Concurrent CVT with haemorrhagic venous infarction and AMI requires individualized multidisciplinary management, antithrombotic selection, and close radiological monitoring. This single case does not establish efficacy or superiority of this therapeutic strategy.

Keywords

Cerebral Venous Sinus Thrombosis, Haemorrhagic Venous Infarction, Myocardial Infarction, Intracranial Haemorrhage, Anticoagulation.

Introduction

Cerebral venous thrombosis (CVT) is an uncommon form of cerebrovascular disease characterized by thrombosis of the cerebral veins and/or dural venous sinuses. Its clinical presentation is highly variable and may include headache, seizures, focal neurological deficits, encephalopathy, altered consciousness, and, in severe cases, coma[1]. Venous outflow obstruction results in increased venous and capillary pressure, impaired cerebral perfusion, disruption of the blood–brain barrier, vasogenic and cytotoxic oedema, and ultimately venous infarction, which may undergo haemorrhagic transformation[2]. Consequently, haemorrhagic venous infarction secondary to CVT differs pathophysiologically from primary spontaneous intracerebral haemorrhage and does not necessarily constitute a contraindication to anticoagulation[3]. Therapeutic anticoagulation remains a fundamental component of acute CVT management because it aims to prevent thrombus propagation, facilitate venous recanalisation, and reduce the risk of further thromboembolic complications, even when haemorrhagic venous infarction is already present[3]. Parenteral anticoagulation, particularly low-molecular-weight heparin (LMWH), is commonly used during the acute phase, whereas direct oral anticoagulants (DOACs) have increasingly emerged as an option for subsequent anticoagulation in appropriately selected patients[4].

Management becomes considerably more complex when CVT with haemorrhagic venous infarction occurs concurrently with acute myocardial infarction (AMI)[5]. CVT provides an indication for therapeutic anticoagulation, whereas AMI may require antiplatelet therapy and, depending on the underlying coronary mechanism and clinical circumstances, invasive coronary evaluation and intervention. Combining anticoagulant and antiplatelet therapies may substantially increase bleeding risk, particularly in a patient with an existing intracranial haemorrhage, mass effect, or thrombocytopenia[6]. Thus, simultaneous cerebral venous and coronary thrombotic events create competing therapeutic priorities in which prevention of further thrombosis must be balanced against the possibility of intracranial haemorrhagic progression.

We report a clinically challenging case of extensive dural venous sinus thrombosis involving the superior sagittal, left transverse, and left sigmoid sinuses, associated with a sizeable haemorrhagic venous infarction and concomitant clinically silent AMI. The case illustrates the diagnostic and therapeutic considerations involved in balancing neurological and cardiovascular thrombotic risks against intracranial bleeding risk through individualized multidisciplinary management[7].

Case Presentation

A 48-year-old man with a known history of diabetes mellitus and hypertension presented with a 2-day history of progressively worsening difficulty in walking associated with weakness of the right upper and lower limbs. During the subsequent 24 hours, his clinical condition progressed, with development of dysarthria, dizziness, confusion, and fluctuations in the level of consciousness. There was no documented history of previous cerebrovascular accident, known thrombophilia, trauma, smoking, systemic illness, coronary intervention, or relevant family history. Importantly, despite the subsequently identified myocardial injury, the patient did not report chest pain or other typical symptoms suggestive of acute myocardial infarction (AMI). The coexistence of progressive focal neurological symptoms and altered sensorium prompted urgent neurological evaluation and neuroimaging.

Clinical Findings

At presentation, the patient's blood pressure was 170/89 mmHg, pulse rate was 92 beats/min, oxygen saturation was 96% on room air, and body temperature was within the normal range. His Glasgow Coma Scale (GCS) score was 13/15 (E3M6V4), indicating impaired consciousness. Neurological examination demonstrated dysarthria, right-sided motor weakness with muscle power of 4/5, brisk right-sided reflexes, and an extensor right plantar response. No significant abnormalities were identified on the documented cardiovascular or respiratory examination. Initial laboratory investigations demonstrated haemoglobin of 16.0 g/dL, leukocyte count of 12.9 × 10^9/L, platelet count of 98 × 10^9/L, serum creatinine of 1.08 mg/dL, and an international normalised ratio (INR) of 1.12. The

thrombophilia evaluation demonstrated normal protein C activity (120%) and antithrombin III activity (111%), whereas protein S activity was mildly reduced at 64%. Serum homocysteine and antiphospholipid testing were reported as normal. Because protein S was measured during an acute thrombotic event and the reduction was borderline, this isolated result was not considered sufficient to establish hereditary protein S deficiency.

Timeline

The clinical course evolved over several days. On Day −2, the patient developed progressive difficulty walking and right-sided hemiparesis. On Day −1, he developed altered sensorium, dysarthria/slurred speech, and dizziness. On Day 0, he presented to the emergency department with a GCS score of E3M6V4 and blood pressure of 170/89 mmHg; non-contrast computed tomography (CT) of the brain demonstrated a left posterior parietal haemorrhagic lesion. During Day 0–1, magnetic resonance imaging (MRI) and magnetic resonance venography (MRV) confirmed a 4.6 × 4.3 × 4.6 cm left posterior parietal haemorrhagic venous infarction associated with thrombosis of the superior sagittal, left transverse, and left sigmoid sinuses. Concurrent cardiac evaluation demonstrated acute inferior/inferoposterior ischaemic changes on electrocardiography (ECG), a rising troponin-I concentration from 5.6 to 16.9 ng/mL, and a left ventricular ejection fraction (LVEF) of 45% with inferior/inferolateral regional wall-motion abnormalities. During hospitalization, multidisciplinary assessment resulted in initiation of therapeutic parenteral anticoagulation together with single-antiplatelet therapy under close neurological monitoring. During the subsequent 24–48 hours, neurological stability was maintained without evidence of haematoma expansion. After clinical stabilization, the patient was transitioned to oral direct anticoagulant therapy, while the antiplatelet strategy was subsequently de-escalated. At approximately 1-week follow-up, the patient was active and independently mobile; follow-up brain MRI demonstrated interval reduction in the haemorrhagic venous infarction without extension of the existing haemorrhage or development of new intracranial bleeding. Myocardial perfusion SPECT demonstrated a medium-sized, moderate-to-severe, predominantly fixed perfusion defect involving the mid-to-basal inferior wall.

Table 1: Summary of initial laboratory parameters

Variables	Patient Value	Reference Range
Hemoglobin	16.0 g/dL	13.0–17.0
Total Leukocyte Count	12.9 × 10^9/L	4.0–11.0
Platelet Count	98 × 10^9/L	150–450
Blood Urea	44 mg/dL	15–40
Serum Creatinine	1.08 mg/dL	0.6–1.2
Serum Sodium	136 mEq/L	135–145
Serum Potassium	4.3 mEq/L	3.5–5.0
Serum Bicarbonate	21 mEq/L	22–28
Prothrombin Time / INR	11.0 s / 1.12	10.0–13.0 s / <1.2
Cardiac Troponin-I	5.6 / 16.9 ng/mL	<0.3
Erythrocyte Sedimentation Rate	38 mm/h	2–10
C-Reactive Protein	6.5 mg/L	<0.5
Protein C Activity	120%	70–140
Protein S Activity	64%	>65
Antithrombin III	111%	84–116
Serum Homocysteine	5.0 µmol/L	5.0–12.0

The borderline Protein S level (64%) was interpreted as an acute-phase or consumption-related fluctuation rather than definitive evidence of hereditary thrombophilia.

Table 2: Diagnostic Imaging and Management of Concomitant CVST and Acute Myocardial Infarction.

Figure	Modality / View	Key Diagnostic Finding	Clinical Relevance / Management Implication
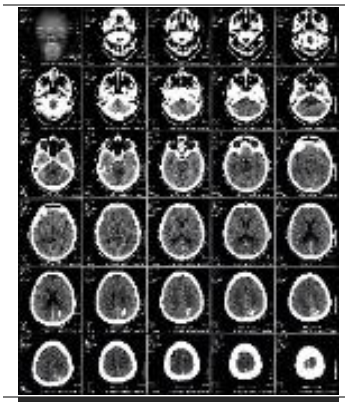	Non-contrast CT brain, axial	Non-contrast CT demonstrated hyperdensity within a dural venous sinus/cortical vein suggestive of acute cerebral venous thrombosis. A separate adjacent hemorrhagic venous infarction was also identified, representing intracranial hemorrhagic transformation secondary to venous outflow obstruction.	Establishes the presence of intracranial hemorrhagic involvement. Despite intracranial hemorrhage related to CVST, therapeutic anticoagulation is generally required, with close neurological monitoring.
	Coronal MRV/CTV	Non-visualisation/filling defect involving the major dural venous sinuses.	Confirms cerebral venous outflow obstruction and provides a baseline for assessment of venous recanalisation.
	Sagittal MRV/CTV	Thrombotic occlusion of the superior sagittal sinus.	Demonstrates the extent of venous sinus involvement and supports the diagnosis of extensive CVST.
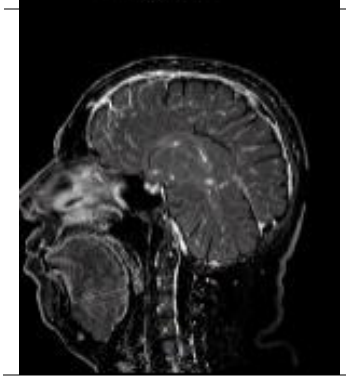	Sagittal T2/FLAIR MRI	Abnormal signal/loss of normal flow-related signal within the superior sagittal sinus with associated parenchymal changes.	Provides additional confirmation of venous thrombosis and delineates associated cerebral oedema or haemorrhagic venous infarction.

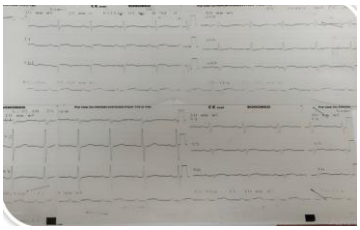	Standard 12-lead ECG	Ischaemic ST-segment/T-wave abnormalities consistent with acute myocardial injury/ischaemia.	Raises suspicion for concomitant acute myocardial infarction and prompts cardiac biomarker assessment and appropriate coronary evaluation.
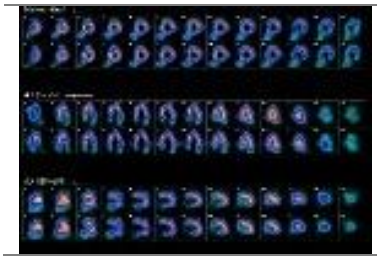	Myocardial perfusion SPECT	Regional myocardial perfusion abnormality demonstrating fixed or reversible perfusion deficit.	Provides objective evidence of myocardial ischaemia/infarction and contributes to subsequent cardiovascular risk stratification and secondary prevention.

Table 3: Timeline of clinical events, investigations, treatment, and outcome.

Time Frame	Clinical Event & Management
Day −2	Onset of progressive difficulty walking and right-sided hemiparesis.
Day −1	Development of altered sensorium, slurred speech, and dizziness.
Day 0	Emergency department presentation; GCS E3M6V4; BP 170/89 mmHg. NCCT shows lef posterior parietal hemorrhage.
Day 0–1	Brain MRI/MRV confirms 4.6 cm left posterior parietal hemorrhagic venous infarction anc superior sagittal, left transverse, and sigmoid sinus thrombosis.
Day 0–1	ECG shows acute inferior/inferoposterior ischemic changes; Troponin-I showed a markec rising pattern, increasing from 5.6 ng/ml to 16.9 ng/ml. TTE shows LVEF 45% witl inferior/inferolateral hypokinesia.
Hospitalization	Multidisciplinary decision: Single antiplatelet therapy + parenteral anticoagulation initiatec under strict neuro-monitoring.
24–48 Hours	Neurological stability maintained; no signs of hematoma expansion.
Discharge	Transitioned to oral DOAC therapy; antiplatelet strategy de-escalated.
1-Week Follow-up	Patient active and mobile. Follow-up brain MRI revealed interval decrease in the hemorrhagic venous infarct without any extension of the bleed or any new intracrania hemorrhage and myocardial perfusion SPECT showed a medium sized moderate to severe predominantly fixed perfusion defect in the mid to basal inferior wall.

Diagnostic Assessment

Initial non-contrast CT of the brain demonstrated haemorrhage involving the left posterior parietal region. Subsequent MRI demonstrated a 4.6 × 4.3 × 4.6 cm cortical/subcortical haemorrhagic lesion extending into the splenium, with surrounding cerebral oedema, mass effect, and approximately 4 mm midline shift. MRV demonstrated absent flow involving the superior sagittal, left transverse, and left sigmoid sinuses, establishing the diagnosis of extensive cerebral venous thrombosis (CVT) associated with haemorrhagic venous infarction.

Despite the absence of chest pain, the markedly elevated cardiac biomarkers prompted cardiovascular evaluation. ECG demonstrated an inferior/inferoposterior ischaemic pattern with ST-segment elevation and reciprocal changes. Serial cardiac troponin-I showed a marked rise from 5.6 to 16.9 ng/mL. Transthoracic echocardiography demonstrated an LVEF of 45% with severe hypokinesia involving the inferior and

inferoposterior/inferolateral walls, preserved right ventricular function with a tricuspid annular plane systolic excursion (TAPSE) of 25 mm, and no intracardiac thrombus. Taken together, the dynamic troponin elevation, ischaemic ECG abnormalities, and regional wall-motion abnormalities supported the diagnosis of concomitant AMI. Coronary angiography was not performed because the treating team considered the intracranial haemorrhage to confer a high procedural and antithrombotic bleeding risk. Consequently, the underlying coronary anatomy and mechanism of myocardial infarction could not be established, and a definitive distinction between type 1 and type 2 myocardial infarction was not possible.

The diagnostic assessment therefore established two simultaneously important conditions: extensive CVT with a sizeable haemorrhagic venous infarction and evidence of clinically silent AMI. The accompanying thrombocytopenia (platelet count 98 × 10^9/L), cerebral oedema, mass effect, and approximately 4-mm midline shift further complicated assessment of the risks and benefits of antithrombotic therapy.

Therapeutic Intervention

Given the coexistence of extensive CVT, a large haemorrhagic venous infarction with mass effect, thrombocytopenia, and concomitant AMI, treatment was determined through multidisciplinary assessment involving neurology, cardiology, and intensive-care teams. Therapeutic anticoagulation with enoxaparin 1 mg/kg subcutaneously every 12 hours was initiated for acute CVT despite the presence of haemorrhagic venous infarction. For the concomitant myocardial infarction, aspirin 100 mg once daily was administered as single-antiplatelet therapy. Dual-antiplatelet therapy was avoided because of the cumulative bleeding risk associated with the sizeable intracranial haemorrhage, thrombocytopenia, and concurrent full-dose anticoagulation.

The patient was managed in a high-dependency setting with close neurological, haemodynamic, and neuroradiological surveillance for clinical deterioration or progression of intracranial haemorrhage. Following clinical stabilization, parenteral anticoagulation was transitioned to oral rivaroxaban 20 mg once daily. Antiplatelet therapy was subsequently de-escalated in view of the ongoing intracranial bleeding risk. This treatment strategy represented an individualized multidisciplinary risk–benefit decision rather than a general therapeutic approach for all patients presenting with simultaneous CVT, haemorrhagic venous infarction, and AMI.

Follow-up and Outcomes

During hospitalization, the patient remained neurologically and haemodynamically stable following initiation of antithrombotic therapy. No neurological deterioration, clinically evident haematoma expansion, recurrent myocardial ischaemia, or clinically significant bleeding was documented. Following stabilization and transition to oral anticoagulation, his level of consciousness returned to normal, his neurological deficits resolved, and he regained independent mobility.

At approximately 1 week, follow-up brain MRI demonstrated an interval reduction in the haemorrhagic venous infarction, with no extension of the pre-existing haemorrhage and no new intracranial bleeding. Myocardial perfusion SPECT demonstrated a medium-sized, moderate-to-severe, predominantly fixed perfusion defect involving the mid-to-basal inferior wall, providing additional evidence of established myocardial injury/infarction without a major reversible component. At this stage, the patient was active and independently mobile, with no documented residual neurological deficit.

Discussion

This case demonstrates the uncommon coexistence of extensive CVT with haemorrhagic venous infarction and clinically silent AMI, producing competing indications for antithrombotic therapy in a patient already at substantial risk of intracranial bleeding. The therapeutic complexity was further increased by the sizeable haemorrhagic lesion, surrounding cerebral oedema, approximately 4-mm midline shift, and thrombocytopenia with a platelet

count of 98 × 10^9/L. Despite these haemorrhagic risk factors, the extensive cerebral venous sinus thrombosis provided a strong clinical indication for anticoagulation. The patient's management therefore required simultaneous consideration of the risk of CVT progression, myocardial ischaemia, and intracranial haemorrhagic expansion.

Haemorrhagic transformation associated with CVT should be distinguished from primary intracerebral haemorrhage. Cerebral venous outflow obstruction causes elevation of venous and capillary pressure, venous congestion, impairment of the blood–brain barrier, cerebral oedema, and ultimately venous infarction with secondary haemorrhage[8]. Because the underlying pathological process is ongoing venous thrombosis rather than primary rupture of a cerebral vessel, the presence of haemorrhagic venous infarction does not, by itself, necessarily preclude therapeutic anticoagulation[3,8]. In the present patient, MR venography demonstrated extensive involvement of the superior sagittal, left transverse, and left sigmoid sinuses, supporting the need to prevent further thrombus propagation despite the presence of intracranial haemorrhage.

An additional diagnostic challenge was the absence of typical cardiac symptoms. The patient did not report chest pain; nevertheless, ECG demonstrated inferior/inferoposterior ischaemic changes with ST-segment elevation and reciprocal changes. Serial cardiac troponin-I showed a marked rise from 5.6 to 16.9 ng/mL, while transthoracic echocardiography demonstrated an LVEF of 45% with severe inferior/inferoposterior regional wall-motion abnormalities. The combination of dynamic cardiac biomarker elevation, ischaemic ECG abnormalities, and corresponding regional ventricular dysfunction supported the diagnosis of acute myocardial infarction despite its clinically silent presentation[9].

Importantly, however, the mechanism of myocardial infarction cannot be established with certainty from the available investigations. Coronary angiography was not performed because of concern regarding the intracranial haemorrhage and the additional antithrombotic exposure that an invasive coronary strategy might entail. Consequently, the coronary anatomy was not defined, and plaque rupture or an acute coronary occlusion was not directly demonstrated. Therefore, although the findings supported acute myocardial infarction, definitive classification as type 1 or type 2 MI would be inappropriate on the available evidence[10]. This diagnostic limitation is important because the mechanism of myocardial injury can influence subsequent antithrombotic and coronary management.

The antithrombotic strategy consequently required an individualized assessment of competing risks. Therapeutic enoxaparin at 1 mg/kg subcutaneously every 12 hours was initiated for CVT, while aspirin 100 mg/day was used as single-antiplatelet therapy for the concomitant myocardial infarction. Dual-antiplatelet therapy was avoided because the patient had a sizeable intracranial haemorrhage, thrombocytopenia, and simultaneous therapeutic anticoagulation, while no coronary stent had been implanted. The patient was managed with close neurological, haemodynamic, and neuroradiological monitoring in a high-dependency setting. Following clinical stabilization, anticoagulation was transitioned to rivaroxaban 20 mg/day, and antiplatelet therapy was subsequently de-escalated in view of the intracranial bleeding risk.

The subsequent clinical and radiological course was favourable. There was no documented neurological deterioration, clinically significant bleeding, recurrent myocardial ischaemia, or evidence of haematoma expansion during treatment. The patient regained full consciousness and independent mobility without documented residual neurological deficit. At approximately 1 week, follow-up brain MRI demonstrated interval reduction in the haemorrhagic venous infarction without extension of the existing haemorrhage or development of new intracranial bleeding. Myocardial perfusion SPECT demonstrated a medium-sized, moderate-to-severe, predominantly fixed perfusion defect involving the mid-to-basal inferior wall, consistent predominantly with established myocardial infarction/scar without a major reversible component.

The mildly reduced protein S activity of 64% should also be interpreted cautiously. Protein S measured

during an acute thrombotic event may not reliably establish an inherited deficiency, and an isolated borderline reduction should therefore not be considered definitive evidence of hereditary thrombophilia. In this patient, protein C and antithrombin III activities were within their reported reference ranges, while homocysteine and antiphospholipid testing were reported as normal. Accordingly, the available thrombophilia evaluation did not establish a definitive hereditary thrombophilic disorder.

Several limitations should be considered when interpreting this case. Most importantly, coronary angiography was not performed; therefore, the coronary anatomy, culprit lesion, and precise mechanism and classification of the myocardial infarction remain uncertain. In addition, the favourable outcome observed in a single patient cannot establish the efficacy, comparative safety, or superiority of the antithrombotic regimen employed. Rather, the case demonstrates the feasibility of an individualized multidisciplinary strategy in an unusual clinical setting characterized by simultaneous thrombotic and haemorrhagic risks. The treatment approach should therefore not be interpreted as a standardized regimen applicable to all patients with concurrent CVT, haemorrhagic venous infarction, and AMI. This distinction is particularly important because treatment decisions in such patients depend on the extent and stability of intracranial haemorrhage, severity of CVT, platelet count, cardiovascular status, coronary intervention requirements, and overall bleeding and thrombotic risks.

Conclusion

This case illustrates the diagnostic and therapeutic complexity of concomitant extensive cerebral venous thrombosis with haemorrhagic venous infarction and clinically silent acute myocardial infarction. Haemorrhagic venous infarction secondary to CVT does not necessarily preclude therapeutic anticoagulation because the underlying pathology remains thrombotic venous outflow obstruction. However, the simultaneous presence of myocardial infarction may introduce an additional indication for antiplatelet therapy, thereby increasing the risk of intracranial bleeding. In this patient, an individualized multidisciplinary strategy incorporating therapeutic anticoagulation, carefully selected single-antiplatelet therapy, intensive neurological and cardiovascular monitoring, and subsequent transition to oral anticoagulation was associated with neurological recovery without documented expansion of the intracranial haemorrhage or clinically significant bleeding. Nevertheless, because coronary angiography was not performed and this represents a single clinical observation, the precise mechanism of myocardial infarction remains uncertain and the favourable outcome should not be interpreted as evidence of superiority of this therapeutic strategy. The case emphasizes the importance of individualized risk–benefit assessment and coordinated neuro-cardiac management when thrombotic and haemorrhagic indications coexist.

Learning Points

- Haemorrhagic venous infarction secondary to cerebral venous thrombosis is pathophysiologically distinct from primary intracerebral haemorrhage and does not necessarily preclude therapeutic anticoagulation.
- Acute myocardial infarction may occur without typical chest pain, particularly in a complex acute neurological presentation; therefore, clinically appropriate evaluation using ECG, serial cardiac biomarkers, and echocardiography may identify otherwise clinically silent myocardial injury.
- Concurrent CVT, haemorrhagic venous infarction, and AMI create competing thrombotic and bleeding risks. Anticoagulant and antiplatelet treatment should therefore be individualized according to the neurological, cardiovascular, haematological, and bleeding profile of the patient rather than extrapolated as a universal regimen.
- When coronary angiography has not been performed, the underlying coronary mechanism and definitive type of myocardial infarction should not be assumed solely from ECG abnormalities, troponin elevation, and regional wall-motion abnormalities.
- A borderline reduction in protein S activity measured during an acute thrombotic episode should be interpreted cautiously and, in isolation,

should not be regarded as definitive evidence of hereditary protein S deficiency.

- Close multidisciplinary collaboration among neurology, cardiology, and critical-care teams, together with serial neurological, haemodynamic, and radiological assessment, is particularly important when treatment of one thrombotic condition may increase the haemorrhagic risk associated with another.
- A favourable outcome in an individual case demonstrates clinical feasibility but does not establish the efficacy, safety, or superiority of a particular combined antithrombotic strategy; longer follow-up and broader evidence are required before such an approach can be generalized.

References

1) Ranjan R, Ken-Dror G, Sharma P. Pathophysiology, diagnosis and management of cerebral venous thrombosis: A comprehensive review. Medicine (Baltimore). 2023;102(48):e36366. doi: 10.1097/MD.0000000000036366.
2) Abdalkader M, Hui F, Amans MR, Raz E, Hanning U, Ma A, Brinjikji W, Malek AM, Oxley TJ, Nguyen TN. Cerebral venous disorders: Diagnosis and endovascular management. J Neuroradiol. 2023;50(6):581-592. doi: 10.1016/j.neurad.2023.06.002.
3) Vellema J, Munckhof AV, Coutinho JM. Cerebral venous thrombosis: Current management, recent advances and future directions. Int J Stroke. 2025;20(10):1177-1187. doi: 10.1177/17474930251393311.
4) Field TS, Lindsay MP, Wein T, Debicki DB, Gorman J, Heran MKS, Levin LA, Lund R, Moharir M, Peeling L, Perera KS, Siegal D, Verreault S, Foley N, Martin C, Smith EE, Mountain A, Mandzia J; Canadian Stroke Best Practice Recommendations Advisory Committee, in collaboration with the Canadian Stroke Consortium. Canadian Stroke Best Practice Recommendations, 7th Edition: Cerebral Venous Thrombosis, 2024 - CORRIGENDUM. Can J Neurol Sci. 2024:1. doi: 10.1017/cjn.2024.350.
5) Benmalek R, Mechal H, Zahidi H, Mounaouir K, Arous S, Benouna MEG, Drighil A, Habbal R. Combined venous and arterial thrombosis revealing underlying myeloproliferative disorder in a young patient: a case report. J Med Case Rep. 2021;15(1):76. doi: 10.1186/s13256-020-02593-5.
6) Zhang W, Pei B, Zhou Y, Li H, Ma W, Zhou B, Zhou C, Jiang H, Ji X. Emerging Targets, Novel Directions, and Innovative Approaches in Thrombosis Therapy. Aging Dis. 2025;17(2):812-848. doi: 10.14336/AD.2024.1688.
7) Carella MC, Carulli E, Loizzi F, Quarta S, Freda A, Basile P, Amati F, Dicorato MM, Latorre MD, Naccarati ML, Lenoci CD, Cicco S, Pontone G, Forleo C, Guaricci AI, Ciccone MM, Santobuono VE. Intersections and Challenges in the Management of Acute Coronary Syndrome and Stroke: Pathophysiology, Treatment Dilemmas, and Integrated Prevention Strategies. J Clin Med. 2025;14(7):2354. doi: 10.3390/jcm14072354.
8) Zhou Y, Jiang H, Wei H, Liu L, Zhou C, Ji X. Venous stroke-a stroke subtype that should not be ignored. Front Neurol. 2022;13:1019671. doi: 10.3389/fneur.2022.1019671.
9) Bellicini MG. Chest pain, troponin, and electrocardiogram: rethinking how we diagnose myocardial ischemia. Postgrad Med J. 2026;102(1211):885-887. doi: 10.1093/postmj/qgaf179.
10) Młynarska E, Czarnik W, Fularski P, Hajdys J, Majchrowicz G, Stabrawa M, Rysz J, Franczyk B. From Atherosclerotic Plaque to Myocardial Infarction-The Leading Cause of Coronary Artery Occlusion. Int J Mol Sci. 2024;25(13):7295. doi: 10.3390/ijms25137295.