PAKISTAN JOURNAL OF Cardiovascular Intervention

OPEN ACCESS

CASE REPORT

Right-Sided Infective Endocarditis Due to Pseudomonas Species Complicated by Secondary Immune Thrombocytopenic Purpura and Renal Dysfunction: A Case Report.

Maha Batool[1], Muhammad Salman Ghani[2], Khawaja Muhammad Usama[2], Sheraz Sajjad[2], Nayab Batool[1], Hassan Abbas[2]

[1]Department of Medicine, Gulab Devi Teaching Hospital, Lahore, Pakistan

[2]Department of Cardiology, Gulab Devi Teaching Hospital, Lahore, Pakistan

Copyright © The Author(s). 2026 This is an open-access article distributed under the terms of the Creative Commons Attribution 4.0 International License, which permits unrestricted use, distribution, and reproduction in any medium, provided the original author and source are credited.

Citation:
Batool M, Ghani MS, Usama KM, Sajjad S, Batool N, Abbas H. Right-Sided Infective Endocarditis Due to Pseudomonas Species Complicated by Secondary Immune Thrombocytopenic Purpura and Renal Dysfunction: A Case Report. PJCVI. 2026; 6(2): XX-XX

Corresponding Author Email:
mahabatool16@gmail.com

DOI: 10.58889/PJCVI.6.2.XX.XX

Funding:
This research received no specific grant from any funding agency in the public, commercial, or not-for-profit sectors.

Conflicts of Interests:
The authors declare no conflict of interest related to this publication.

Received 17/03/2026
Accepted 11/07/2026
First Published 23/11/2026

Abstract

Background: Right-sided infective endocarditis caused by Pseudomonas aeruginosa is uncommon. Secondary immune thrombocytopenic purpura and renal dysfunction further complicate its diagnosis and treatment.

Case Presentation: A 40-year-old woman presented with a one-month history of intermittent fever, progressive dyspnea, and palpitations. Examination revealed features of right-sided heart failure and severe tricuspid regurgitation. Transthoracic echocardiography demonstrated a 1.2-cm mobile vegetation on the anterior tricuspid leaflet, severe tricuspid regurgitation, severe pulmonary hypertension, and right-sided chamber dilatation. Three independently collected blood culture sets grew Pseudomonas aeruginosa. Laboratory investigations revealed severe thrombocytopenia with a platelet count of 20,000/µL, giant platelets on peripheral smear, and an elevated immature platelet fraction of 14.8%, supporting peripheral immune-mediated platelet destruction. Serum creatinine was 2.3 mg/dL with an estimated glomerular filtration rate of 26 mL/min/1.73 m², consistent with acute-on-chronic kidney disease.

Management and Results: Renal-adjusted intravenous meropenem and levofloxacin were administered for six weeks. Aminoglycosides were avoided because of nephrotoxicity. Corticosteroids, intravenous immunoglobulin, and platelet transfusion were not required. Fever resolved by day five, repeat blood cultures became sterile, and platelet counts increased to 110,000/µL by week two and 145,000/µL at six-week follow-up. Renal function remained stable without dialysis, while vegetation size decreased on repeat echocardiography.

Conclusion: Treating the underlying infection resulted in bacteriological clearance and platelet recovery. This case emphasizes the diagnostic value of immature platelet fraction and the importance of renal-adjusted, multidisciplinary management.

Keywords

Infective Endocarditis, Pseudomonas Aeruginosa, Immune Thrombocytopenic Purpura, Chronic Kidney Disease, Tricuspid Valve, Pakistan.

Introduction

Infective endocarditis remains associated with substantial morbidity and mortality despite advances in diagnosis and treatment[1,2]. Hematologic abnormalities, including thrombocytopenia, are frequently observed and usually reflect sepsis or consumptive processes[3]. Secondary immune thrombocytopenic purpura (ITP) triggered by infection is uncommon but has been reported in association with bacterial infections, including IE[4,5]. Renal dysfunction further complicates management by limiting antimicrobial and immunomodulatory options[6].

Case Presentation

A 40-year-old woman presented to the cardiac emergency department with intermittent fever, progressive shortness of breath, and palpitations for one month. She had no known history of rheumatic heart disease, intravenous drug use, recent invasive procedures, or autoimmune disorders.

On examination, she was febrile and tachycardic, with raised jugular venous pressure, peripheral edema, and a pansystolic murmur best heard at the left lower sternal border, suggestive of tricuspid regurgitation. Transthoracic echocardiography demonstrated severe tricuspid regurgitation, severe pulmonary hypertension, and preserved left ventricular systolic function (ejection fraction 60%). It showed a dilated right atrium and ventricle with a mobile, echogenic mass (approximately 1.2 cm in maximal dimension) attached to the anterior leaflet of the tricuspid valve, consistent with vegetation. The tricuspid valve also demonstrated thickened leaflet tips, non-coaptation, and restricted systolic motion, resulting in severe tricuspid regurgitation.

The severe pulmonary hypertension (estimated pulmonary artery systolic pressure 65 mmHg by tricuspid regurgitation jet velocity) was attributed to longstanding volume and pressure overload from right-sided IE with severe tricuspid regurgitation, rather than primary pulmonary arterial disease, based on the absence of prior pulmonary history and the echocardiographic pattern of right heart dilation with preserved pulmonary vasculature on imaging, consistent with right-sided infective endocarditis (Figure 1). Ultrasonography of the abdomen revealed hepatomegaly (19.7 cm) with grade 2 fatty change and splenomegaly (12.7 cm) with preserved echotexture.

Laboratory investigations showed severe thrombocytopenia (20,000/µL). Coagulation studies (prothrombin time, activated partial thromboplastin time, and fibrinogen) were within normal limits, and D-dimer was mildly elevated but not in a range consistent with DIC. Peripheral blood smear demonstrated marked anisopoikilocytosis, microcytic hypochromic red cells with macrocytosis, giant platelets (megathrombocytes), and neutrophilic leukocytosis, without schistocytes or red cell fragmentation (Figure 2).

The immature platelet fraction was elevated at 14.8%, supporting peripheral platelet destruction. Renal function was impaired with serum creatinine 2.3 mg/dL (eGFR estimated at 26 mL/min/1.73 m² by CKD-EPI equation) and urea 171 mg/dL. Urinalysis revealed mild proteinuria (1+) without active urinary sediment or hematuria. Renal ultrasonography showed bilaterally reduced kidney size with increased cortical echogenicity, consistent with underlying chronic parenchymal disease. The patient reported no prior nephrology follow-up, but the chronic echopattern and reduced kidney size were consistent with pre-existing chronic kidney disease (CKD stage G4). In the context of sepsis from infective endocarditis, this was characterized as acute-on-chronic kidney disease. Inflammatory markers were elevated (CRP 23.9 mg/L). Autoimmune workup, including ANA and anti–double-stranded DNA antibodies, was negative.

Three sets of blood cultures, drawn from separate venipuncture sites at admission, yielded Pseudomonas aeruginosa (identified by MALDI-TOF mass spectrometry) in all three sets, with both aerobic and anaerobic bottles turning positive within 24 hours of incubation, consistent with persistent bacteremia. The isolate was sensitive to amikacin, levofloxacin, ciprofloxacin, and meropenem, and resistant to imipenem.



Figure 1: Transthoracic echocardiography (apical four-chamber view) demonstrating a mobile, echogenic mass attached to the tricuspid valve leaflet (white arrow), consistent with tricuspid valve vegetation suggestive of Infective Endocarditis.

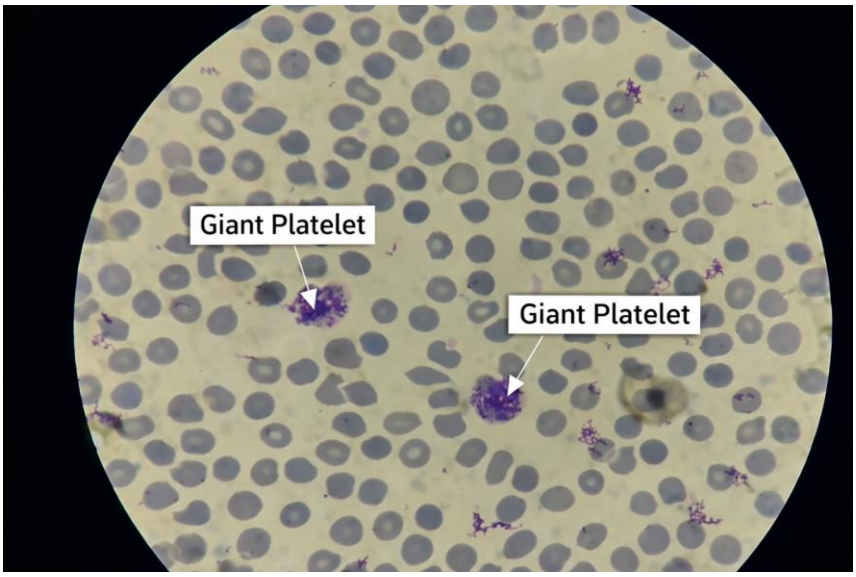

Figure 2: Peripheral blood smear showing thrombocytopenia with the presence of giant platelets (megathrombocytes) (white arrowheads), in keeping with Immune Thrombocytopenic Purpura. Red blood cells appear morphologically unremarkable.

Diagnostic Criteria

The diagnosis of infective endocarditis was established using the modified Duke criteria, with two major criteria fulfilled: (1) persistently positive blood cultures for Pseudomonas aeruginosa (a typical organism for IE) from three independently drawn blood culture sets, with persistent positivity over 24 hours; and (2) echocardiographic evidence of tricuspid valve vegetation — a mobile, echogenic mass (approximately 1.2 cm) attached to the anterior tricuspid leaflet, confirmed on transthoracic echocardiography (TTE). Transesophageal echocardiography (TEE) was considered but deferred after the patient demonstrated clinical improvement on medical therapy, and the TTE findings were deemed diagnostically adequate by the endocarditis team. Minor criteria fulfilled included: (i) fever ≥38°C at presentation, and (ii) predisposing condition in the form of structural cardiac changes consistent with right-sided IE. Vascular phenomena and immunological findings were not scored as minor Duke criteria, as the clinical features of right heart failure do not constitute vascular phenomena per the modified Duke criteria definition.

Management

Management was guided by the 2015 American Heart Association (AHA) guidelines for infective endocarditis (Baddour et al.) and the 2023 European Society of Cardiology (ESC) guidelines, with additional input from nephrology and hematology teams[7,8]. An endocarditis team ("endocarditis team" approach) was convened per guideline recommendation to coordinate multidisciplinary decision-making.

Antimicrobial Therapy

Per AHA and ESC guidelines, treatment of Pseudomonas aeruginosa endocarditis mandates prolonged bactericidal therapy, preferably with an antipseudomonal beta-lactam combined with an aminoglycoside or fluoroquinolone[7,8]. In this patient, concurrent renal dysfunction (eGFR <30 mL/min/1.73 m²) precluded aminoglycoside use due to nephrotoxicity risk. The antibiotic regimen was therefore tailored based on culture sensitivity and renal function: Intravenous Meropenem 1 g every 24 hours (renally adjusted from the standard 2 g every 8 hours dosing) combined with Levofloxacin 500 mg every 48 hours (renally adjusted per creatinine clearance). Imipenem was excluded based on documented in vitro resistance. This dual-agent strategy was selected to provide broad bactericidal coverage against Pseudomonas aeruginosa while minimizing nephrotoxic risk; although formal synergy testing was not performed in this case, in vitro data and clinical experience support the combination of carbapenems with fluoroquinolones for multidrug-resistant Pseudomonas IE in patients where aminoglycosides are contraindicated[8,9]. Per AHA guidelines, a minimum of six weeks of intravenous antibiotic therapy is recommended for right-sided Pseudomonas IE[7]. Given the absence of routine pharmacokinetic monitoring for levofloxacin in most clinical settings, dose optimization was guided by creatinine clearance-based renal adjustment protocols and clinical response, with serial reassessment of renal function informing any further dose modifications. Serial blood cultures were obtained to confirm bacteremia clearance.

Surgical Evaluation

Surgical indications for right-sided IE per ESC and AHA guidelines include large vegetations (>20 mm) with recurrent septic pulmonary emboli, organisms difficult to eradicate (including Pseudomonas), persistent bacteremia after more than one week of appropriate therapy, or right heart failure refractory to medical management[7,8]. In this patient, surgery was considered, given the severe tricuspid regurgitation with severe pulmonary hypertension and right ventricular dilatation. However, the patient responded to medical therapy with hemodynamic stabilization, and the high perioperative risk associated with thrombocytopenia, renal dysfunction, and ongoing infection informed the decision to continue conservative management with close surgical surveillance. A formal heart team discussion documented this shared decision.

Management of Immune Thrombocytopenic Purpura

Management of secondary ITP followed the 2019 International Consensus Report on ITP[10] and the American Society of Hematology (ASH) 2019 ITP

guidelines, adapted to the context of active infection[11]. Given that the underlying infection was the presumed driver of immune-mediated platelet destruction, antimicrobial therapy targeting Pseudomonas was prioritized as definitive treatment of the ITP trigger. A conservative transfusion threshold was adopted, with platelet transfusion reserved for active hemorrhage or planned invasive procedures, consistent with ASH guideline recommendations[11]. Corticosteroids (Prednisolone 1 mg/kg/day) were introduced cautiously after blood culture sterilization was confirmed, with close monitoring for infection reactivation. Intravenous immunoglobulin (IVIg) at 1 g/kg/day for two days was held in reserve for refractory thrombocytopenia or bleeding emergency, per guideline-recommended rescue therapy[10,11]. Gastrointestinal hemorrhage prophylaxis with a proton pump inhibitor was initiated. All antiplatelet agents and non-steroidal anti-inflammatory drugs were withheld.

Renal Management

Renal management followed KDIGO (Kidney Disease: Improving Global Outcomes) guidelines for acute-on-chronic kidney disease (KDIGO 2024). The pre-existing CKD (stage G4, eGFR 26 mL/min/1.73 m²) with small, echogenic kidneys on imaging and no prior nephrology records provided the baseline context. Acute-on-CKD was attributed to the combination of sepsis-related hemodynamic instability, impaired renal perfusion from right heart failure, and the systemic inflammatory response to endocarditis. Nephrotoxic agents were avoided or renally adjusted throughout the admission. Fluid balance was carefully monitored, given co-existing right heart failure and impaired renal perfusion. Renal function was monitored with daily serum creatinine, urea, and electrolytes. Renal replacement therapy was not required. Nephrology was involved in ongoing dose optimization and surveillance for further deterioration[12].

Patient Progress and Outcome

Following initiation of therapy, the patient showed marked clinical improvement, with defervescence by day 5, resolution of dyspnea, and hemodynamic stabilization. Repeat blood cultures obtained at 72 hours and one week after antibiotic initiation were sterile, confirming bacteremia clearance. Platelet counts gradually improved under antibiotic therapy alone, reaching 110,000/µL by week two, without the need for corticosteroids or IVIg during the admission. A six-week course of intravenous antibiotic therapy was completed in total, as recommended by AHA guidelines for right-sided Pseudomonas IE[7]. Renal function remained static but stable throughout admission, with serum creatinine 2.4 mg/dL at discharge, without requirement for renal replacement therapy. Repeat transthoracic echocardiography at week four demonstrated interval reduction in vegetation size and persistent severe tricuspid regurgitation with stable right ventricular dimensions, supporting continued medical management. The patient was discharged in a stable condition with close cardiology, nephrology, and hematology follow-up arranged at four weeks. At the six-week outpatient review, platelet count was 145,000/µL, and serum creatinine had improved marginally to 2.1 mg/dL, consistent with resolution of the acute-on-CKD component.

Clinical Timeline

Time Course	Key Events
1 month prior	Onset of fever, dyspnea, palpitations
Admission	Severe TR, pulmonary hypertension, platelets 20,000/µL
Day 1–2	Echocardiography (TTE) suggestive of tricuspid IE
Day 3	Blood cultures positive for Pseudomonas species
Day 4	Initiation of renal-adjusted IV antibiotics
Week 1	Improvement in fever and respiratory symptoms
Week 2	Platelet count increased to 110,000/µL
Discharge	Hemodynamically stable; blood cultures sterile; creatinine 2.4 mg/dL at discharge

Differential Diagnosis

Severe thrombocytopenia in this patient prompted evaluation for alternative etiologies, including sepsis-related thrombocytopenia, disseminated intravascular coagulation, thrombotic thrombocytopenic purpura, hemolytic uremic syndrome, hypersplenism, and bone marrow suppression. Normal coagulation parameters, the absence of schistocytes typical of microangiopathy, an elevated immature platelet fraction, and the lack of pancytopenia favored a diagnosis of secondary immune thrombocytopenic purpura over consumptive or marrow-related causes.

Discussion

Thrombocytopenia occurs in up to one-third of patients with infective endocarditis and is associated with worse outcomes[3,13]. Secondary ITP in IE is rare but may result from immune-mediated platelet destruction triggered by bacterial antigens through molecular mimicry or immune complex formation[5,14]. The elevated immature platelet fraction (IPF) of 14.8% observed in this patient is consistent with peripheral platelet destruction rather than bone marrow suppression. IPF, representing newly released reticulated platelets, has emerged as a reliable biomarker for distinguishing hyperdestructive thrombocytopenia from hypoproductive causes, with values above 9.5% supporting peripheral destruction[15]. This differentiation has direct therapeutic implications: peripheral destruction warrants immunomodulatory therapy, whereas marrow failure would require distinct management strategies.

Right-sided IE accounts for approximately 5–10% of IE cases and most commonly involves the tricuspid valve[16]. Although classically associated with intravenous drug use, right-sided IE occurs across diverse patient populations without traditional risk factors, as illustrated by this case[17]. Pseudomonas endocarditis is uncommon, accounting for fewer than 5% of all IE cases, and is associated with higher rates of treatment failure, systemic embolism, and mortality compared with streptococcal and staphylococcal IE[9]. The organism's capacity for biofilm formation, intrinsic resistance mechanisms, and production of virulence factors, including exotoxins and proteases, renders it particularly difficult to eradicate[8,9]. Current AHA and ESC guidelines acknowledge the challenges of Pseudomonas IE and recommend at least six weeks of combination bactericidal therapy guided by susceptibility testing, with a low threshold for surgical consultation[7,8].

Renal dysfunction, present at admission with serum creatinine 2.3 mg/dL, further complicated management on multiple fronts. First, nephrotoxic antimicrobials, including aminoglycosides and vancomycin, were precluded, limiting bactericidal synergy options for Pseudomonas[18]. Second, renal impairment alters drug pharmacokinetics, requiring dose adjustments to maintain therapeutic drug levels while avoiding toxicity[18]. Third, CKD represents an independent risk factor for worse IE outcomes and is associated with higher surgical risk[6,12]. The KDIGO framework was applied to guide fluid management, nephrotoxin avoidance, and renal dose adjustment throughout the admission[12].

The intersection of active infection and secondary ITP created a therapeutic paradox. Immunosuppressive therapy with corticosteroids, the cornerstone of ITP management per ASH and international consensus guidelines, carries the risk of blunting host immune responses and potentiating infection[10,13]. Conversely, delaying ITP-directed therapy perpetuates hemorrhagic risk at platelet counts below 20,000/μL. The strategy adopted in this case – prioritizing infection control with targeted antibiotics, deferring corticosteroids until blood culture sterilization, and reserving IVIg for rescue – represents a pragmatic, evidence-informed approach consistent with the 2019 International Consensus Report on IT[10]. The subsequent spontaneous rise in platelet count to 110,000/μL following effective antimicrobial treatment reinforces the primacy of treating the underlying infectious trigger in secondary ITP.

This case reinforces the value of the multidisciplinary "endocarditis team" approach recommended by both the AHA and ESC guidelines, comprising cardiologists, infectious disease specialists, cardiac surgeons, hematologists, and nephrologists[7,8].

Complex cases involving rare complications such as secondary ITP demand structured team-based decision-making, serial reassessment of surgical candidacy, and integrated guideline application across specialties.

Conclusion

This case describes a rare and clinically challenging triad of right-sided Pseudomonas infective endocarditis, secondary immune thrombocytopenic purpura, and chronic kidney disease. The elevated immature platelet fraction provided a valuable, non-invasive indicator of peripheral platelet destruction that guided diagnosis and management. Antimicrobial therapy aligned with AHA/ESC guidelines, incorporating renal dose adjustment and avoidance of nephrotoxins, achieved bacteriological cure and served as definitive treatment of the ITP trigger. Sequential introduction of corticosteroids following infection control illustrates a pragmatic strategy for managing secondary ITP in the context of active bacteremia, consistent with international consensus recommendations. A structured multidisciplinary endocarditis team approach, with longitudinal reassessment of surgical candidacy and integrated nephrology and hematology input, was central to the favorable outcome. Clinicians should maintain vigilance for immune-mediated hematological complications in IE, as early recognition and tailored, guideline-directed management can substantially improve prognosis.

Acknowledgment

We are thankful to the staff of the Department of Cardiology, Gulab Devi Teaching Hospital, Lahore for providing us a platform to conduct this study.

References

1) Cahill TJ, Prendergast BD. Infective endocarditis. Lancet. 2016;387:882–893. doi: 10.1016/S0140-6736(15)00067-7
2) Habib G, Lancellotti P, Antunes MJ, Bongiorni MG, Casalta JP, Del Zotti F, et al. 2015 ESC guidelines for the management of infective endocarditis. Eur Heart J. 2015;36:3075–3128. doi: 10.1093/eurheartj/ehv319.
3) Thuny F, Grisoli D, Collart F, Habib G, Raoult D. Management of infective endocarditis: challenges and perspectives. Lancet. 2012;379(9819):965-975. doi: 10.1016/S0140-6736(11)60755-1.
4) Arnold DM, Nazi I, Warkentin TE, Smith JW, Toltl LJ, George JN, Kelton JG. Approach to the diagnosis and management of drug-induced immune thrombocytopenia. Transfus Med Rev. 2013;27(3):137-145. doi: 10.1016/j.tmrv.2013.05.005.
5) Cines DB, Blanchette VS. Immune thrombocytopenic purpura. N Engl J Med. 2002;346(13):995-1008. doi: 10.1056/NEJMra010501.
6) Stevens PE, Levin A; Kidney Disease: Improving Global Outcomes Chronic Kidney Disease Guideline Development Work Group Members. Evaluation and management of chronic kidney disease: synopsis of the kidney disease: improving global outcomes 2012 clinical practice guideline. Ann Intern Med. 2013;158(11):825-30. doi: 10.7326/0003-4819-158-11-201306040-00007.
7) Baddour LM, Wilson WR, Bayer AS, Fowler Jr VG, Tleyjeh IM, Rybak MJ, et al. Infective endocarditis in adults: diagnosis, antimicrobial therapy, and management of complications. Circulation. 2015;132:1435–1486. doi: 10.1161/CIR.0000000000000296
8) Delgado V, Ajmone Marsan N, de Waha S, Bonaros N, Brida M, Burri H, et al. 2023 ESC Guidelines for the management of endocarditis. Eur Heart J. 2023;44(39):3948-4042. doi: 10.1093/eurheartj/ehad193. Erratum in: Eur Heart J. 2023;44(45):4780. doi: 10.1093/eurheartj/ehad625. Erratum in: Eur Heart J. 2024;45(1):56. doi: 10.1093/eurheartj/ehad776. Erratum in: Eur Heart J. 2025 Mar 13;46(11):1082. doi: 10.1093/eurheartj/ehae877.
9) Morpeth S, Murdoch D, Cabell CH, Karchmer AW, Pappas P, Levine D, et al. Non-HACEK gram-negative bacillus endocarditis. Ann Intern Med. 2007;147(12):829-835. doi: 10.7326/0003-4819-147-12-200712180-00002.
10) Provan D, Arnold DM, Bussel JB, Chong BH, Cooper N, Gernsheimer T, Ghanima W, Godeau B, González-López TJ, Grainger J, Hou M, Kruse C, McDonald V, Michel M, Newland AC, Pavord S, Rodeghiero F, Scully M, Tomiyama Y, Wong RS, Zaja F, Kuter DJ. Updated international consensus report on the investigation and management of primary immune thrombocytopenia. Blood Adv. 2019;3(22):3780-3817. doi: 10.1182/bloodadvances.2019000812.
11) Neunert C, Terrell DR, Arnold DM, Buchanan G, Cines DB, Cooper N, et al. American Society of Hematology 2019 guidelines for immune thrombocytopenia. Blood Adv. 2019;3(23): 3829–3866. doi: 10.1182/bloodadvances.2019000966

12) Disease K, Group IG. KDIGO 2024 Clinical Practice Guideline for the Evaluation and Management of Chronic Kidney Int Suppl. 2024;114(Suppl 1):S117–S314.
13) Netzer RO, Zollinger E, Seiler C, Cerny A. Infective endocarditis: clinical spectrum, presentation and outcome. An analysis of 212 cases 1980-1995. Heart. 2000;84(1):25-30. doi: 10.1136/heart.84.1.25.
14) Voulgaris E, Skoutelis A. Immune thrombocytopenia associated with infections. Mediterr J Hematol Infect Dis. 2014;6:e2014040.
15) Briggs C, Hart D, Kunka S, Oguni S, Machin SJ. Immature platelet fraction measurement. Transfus Med. 2006;16:101–109. doi: 10.1111/j.1365-3148.2006.00654.x
16) Akinosoglou K, Apostolakis E, Marangos M. Right-sided infective endocarditis. Eur J Cardiothorac Surg. 2012;42:470–479. doi: 10.1093/ejcts/ezs084.
17) Moss R, Munt B. Injection drug use and right-sided endocarditis. Heart. 2003;89:577–581. doi: 10.1136/heart.89.5.577
18) Nolin TD, Naud J, Leblond FA, Pichette V. Kidney disease and drug metabolism. Clin Pharmacol Ther. 2008;83:898–903. doi: 10.1038/clpt.2008.59